



Novel technique: direct access partial nephrectomy approach through a transperitoneal working space (Roskilde technique)

Nessn H. Azawi, Maria Skydt Lindgren, Ida Uhrskov Ibsen, Sara Tolouee, Naomi Nadler, Claus Dahl & Mikkel Fode


To cite this article: Nessn H. Azawi, Maria Skydt Lindgren, Ida Uhrskov Ibsen, Sara Tolouee, Naomi Nadler, Claus Dahl & Mikkel Fode (2019) Novel technique: direct access partial nephrectomy approach through a transperitoneal working space (Roskilde technique), Scandinavian Journal of Urology, 53:4, 261-264, DOI: [10.1080/21681805.2019.1624609](https://doi.org/10.1080/21681805.2019.1624609)

To link to this article: <https://doi.org/10.1080/21681805.2019.1624609>



Published online: 07 Jun 2019.



Submit your article to this journal 



Article views: 32

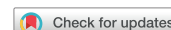

View related articles 





View Crossmark data 

ARTICLE



Novel technique: direct access partial nephrectomy approach through a transperitoneal working space (Roskilde technique)

Nessn H. Azawi^{a,b} , Maria Skydt Lindgren^a, Ida Uhrskov Ibsen^a, Sara Tolouee^a , Naomi Nadler^a, Claus Dahl^a and Mikkel Fode^a

^aDepartment of Urology, Zealand University Hospital, Roskilde, Denmark; ^bInstitute of Clinical Medicine, University of Copenhagen, Copenhagen, Denmark

ABSTRACT

Objectives: To describe a direct access partial nephrectomy technique through a transperitoneal working space (Roskilde technique).

Materials and methods: Prospective single-center descriptive study between April 2015 and January 2017. The surgical outcomes are evaluated according to the Trifecta criteria (negative margins, warm ischemia time < 20 min and a Clavien-Dindo complication score < 3).

Surgical procedure: The same access to the transperitoneal cavity as in a Standard transperitoneal Partial Nephrectomy was used. A direct access was established by incision of the peritoneum directly onto the renal fascia. The renal vessels and tumor were identified and the tumor removed with standard technique. The perinephric fat and peritoneum were then closed with a running suture.

Results: In total, 122 patients underwent the Roskilde technique. The mean age was 62.2 years, the median Padua score was 12 (IQR = 9–12) and the median tumor size was 32 mm (IQR = 12–90). The median operative time was 101 min (IQR = 90–125). The trifecta achievement criteria goal was achieved in 116/122 (95%), with a median warm ischemia time of 8 min (IQR = 0–12).

Conclusions: The Roskilde technique is safe and feasible. It can be performed on complex renal masses, and it seems to result in short operative times and high Trifecta achievement.

Trial registration: None

ARTICLE HISTORY

Received 11 January 2019

Revised 8 May 2019

Accepted 23 May 2019

KEYWORDS

Partial nephrectomy; renal cancer; retroperitoneal partial nephrectomy; robot assisted partial nephrectomy; transperitoneal partial nephrectomy

Introduction

The rate of incidentally detected small (< 4 cm) asymptomatic renal tumors has increased dramatically due to a rise in computed tomography (CT) scans for other purposes [1]. Nephron-sparing surgery has become the gold standard for small renal masses whenever technically feasible [2] because of its equivalent oncological results compared to radical nephrectomy [3]. Robot-assisted partial nephrectomy has emerged as a viable option in such procedures [4–6]. Here, a transperitoneal approach is the most common, as it offers a larger working space compared to the retroperitoneal approach. Meanwhile, the retroperitoneal approach, traditionally used for open surgeries, offers many advantages, including direct access to the kidney and renal hilum, reduction of the operative time and minimization of the dissection during surgery. In addition, it has been reported that the transperitoneal approach may increase post-operative adhesion and complications [7, 8]. Due to these factors, retrospective studies have explored the retroperitoneal robot-assisted partial nephrectomy and shown that this approach may reduce the operating time and length of the post-operative hospital stay, especially for posterior and laterally located tumors [9]. On the other hand, these studies

have also acknowledged difficulties caused by limited working space and a lack of surgical landmarks [10]. Many criteria have been used to evaluate the quality of surgical approaches, some focusing on the safety and others on the oncological outcome. To encompass both perspectives, Buffi et al. [11] developed an important system to evaluate the optimal outcome after nephron-sparing surgery called Trifecta, which is defined as negative margins, warm ischemia time (WIT) < 20 min and a Clavien-Dindo complication score < 3.

We propose that a novel approach of direct access partial nephrectomy through a transperitoneal working space (Roskilde technique) may preserve the retroperitoneal cavity, while providing quick access to the renal hilum and reducing unnecessary dissection to the transperitoneal organs. These advantages, combined with a large working space through the transperitoneal access, may lead to a maximal benefit of this new approach. Here, we describe the Roskilde technique for the first time.

Materials and methods

Patients with renal tumors were eligible for robot-assisted partial nephrectomy if surgery was deemed technically

possible, regardless of tumor size and renal function. The Roskilde technique for laparoscopic partial nephrectomies was introduced at our center in April 2015 and all subsequent procedures were performed with this technique. All patients operated on between April 2015 and January 2017 were included in the study. All surgeries were performed by the same team of experienced surgeons.

Information on age, gender, operative time, WIT, surgical margin, conversion rates, length of hospital stay (LOS), reoperation, 30-day peri- and post-operative complications according to the Clavien-Dindo classification, estimated glomerular filtrations rate (eGFR) before and after surgery and 30-day mortality rate were collected. Tumors were classified according to the Padua scoring system (the preoperative aspects and dimensions were used for the anatomical score) [12].

Achievement of the trifecta criteria (negative margins, WIT < 20 min and Clavien-Dindo complication score < 3) was considered the main endpoint. All tests were two-sided and the significance level was set at $p < 0.05$.

The study was approved by the data protection agency and the Danish Patient Safety Authorities in accordance with Danish law (case no. 3-3013-2056/1).

Roskilde technique

The same access to the transperitoneal space as in the standard transperitoneal technique was used. The colon and duodenum on the right side, and the colon, pancreas and spleen on the left side were not mobilized. In some cases of large livers, the right lobe of the liver needed mobilization (Figure 1).

A direct access was established by incision of the peritoneum directly onto the renal fascia away from the colon through the whole length of kidney, entering the perinephric fat at the right or left paracolic gutter space (Figure 2). Depending on the location of the tumor, the dissection continued toward the renal vessels on the opposite side of the tumor with degloving of the kidney (Figure 3). If the tumor was located by the renal hilum, some fat layers were left on the surface of tumor and the vessel dissection was performed toward the tumor with a close contact to the vessel walls. In case of toxic perinephric fat, some fat layers were left on the kidney surface to simplify the dissection. This

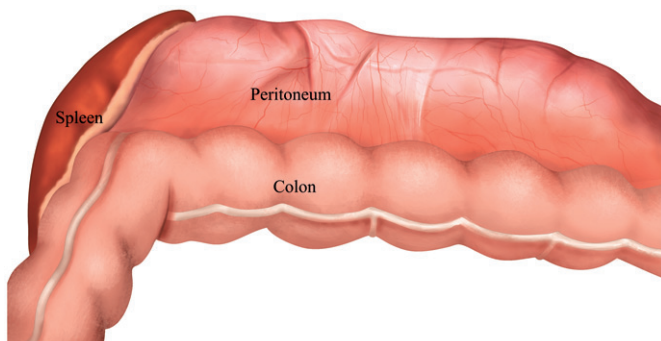


Figure 1. Standard view for the transperitoneal approach for robot-assisted renal surgery.

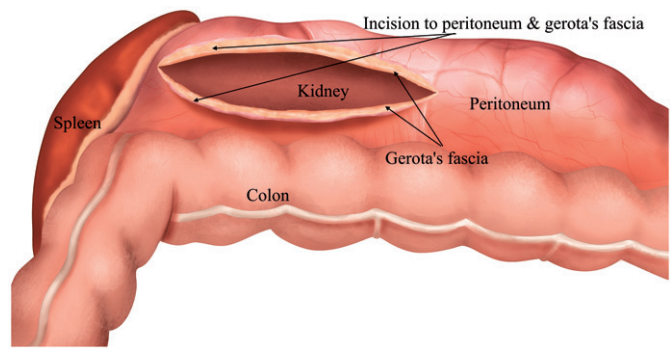


Figure 2. Direct access established by regular incision to the peritoneum direct to the renal fascia.

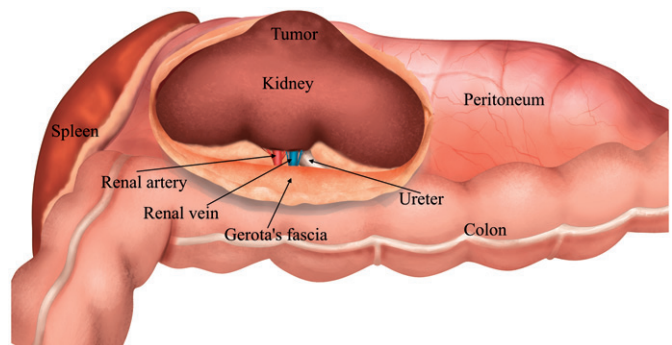


Figure 3. Degloving the kidney and identification of the renal hilum.

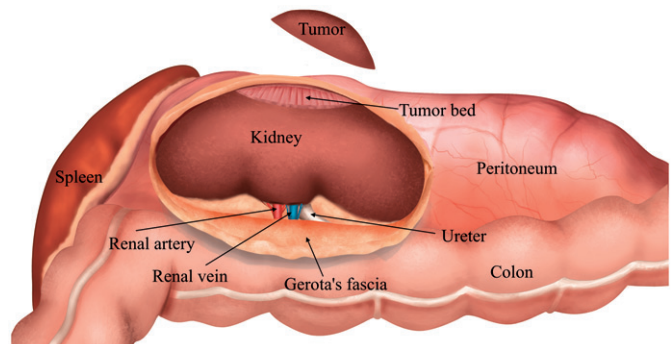


Figure 4. Excision or enucleation of the renal mass with a standard technique.

approach allowed the surgeon to access the peripheral branches of renal vessels directly, which gave the opportunity to perform the selective arterial clamping technique. Here, peripheral renal vessels supplying the tumor directly were controlled, with or without the firefly technique. Afterward the dissection of the hilum continued close to the main renal artery and vein. The tumor margins were identified with the help of endoscopic ultrasound. Either the main renal arteria or selected renal arteria branches were clamped or the off-clamp technique was used during tumor excision or tumor enucleation (Figure 4). The excision bed was closed with 2-0 running monofilament absorbable (Biosorb) sutures, and the kidney parenchyma was closed with 2-0 braided absorbable (Polysorb) interrupted sutures, all with the sliding technique (Figure 5). Perinephric fat and peritoneum were

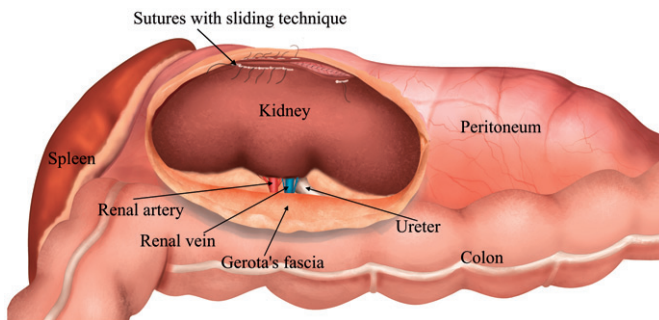


Figure 5. Reconstruction of renal tumor bed with standard renorrhaphy sliding technique.

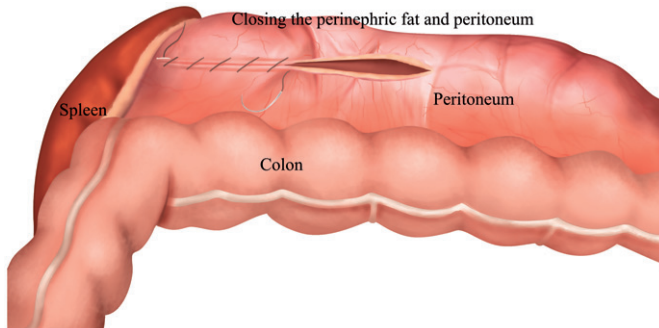


Figure 6. Perinephric fat and peritoneum closed with a running suture preserving the retroperitoneal operative space.

then closed with a running 2-0 Polysorb suture to preserve the retroperitoneal operative space (Figure 6).

Results

In total, 246 patients were diagnosed with RCC in the study period. Thirty-seven (15%) patients had metastatic disease, 10 (4%) patients were managed by active surveillance, five (2%) patients underwent ablation therapy, three (1.2%) patients underwent open partial nephrectomies due to difficulties with the anesthesia and 69 (28%) patients underwent radical nephrectomies.

In total, 122 (49.6%) patients underwent partial nephrectomies with the Roskilde technique. There were 50 (41%) females and 72 (59%) males. The mean age was 62.2 years (standard deviation [SD] = 10.8; confidence interval [CI] = 60.8–63.7). A Padua score of 6–7 was reported in 18 (14.8%) patients, a Padua score of 8–9 was reported in 22 (18%) patients and a Padua score over 10 was reported in 82 (67.2%) patients. The median Padua score was 12 (IQR = 9–12). Thirty-three patients (27%) underwent off-clamp technique and 18 patients (14.7%) underwent the selective clamp technique. The median WIT was 8 min (IQR = 0–12). Final histological findings are shown in Table 1. The median tumor size was 32 mm (IQR = 12–90). Perioperative bleeding was 100 ml (IQR = 0–850). No conversions to open surgery were performed. The median operative time was 101 min (IQR = 90–125).

Positive surgical margins were reported in 2/122 (1.6%). A complication with a 30 day Clavien-Dindo score of ≥ 3 was

Table 1. Pathological outcome after partial nephrectomy.

Pathological results	Roskilde technique, n (%)
Benign	32 (26.23)
T1a	64 (52.46)
T1b	18 (14.75)
T2a	2 (1.64)
T2b	1 (0.82)
T3a	5 (4.1)
Total	122 (100)

Table 2. Complication rate within 30 post-operative days according to Clavien-Dindo classification.

Clavien-Dindo score	Roskilde technique, n (%)
No complications	81 (66.39)
1	17 (13.93)
2	23 (18.85)
3	1 (0.82)
4	—
5	—
Total	122 (100.00)

reported in one (0.8%) patient who needed reoperation due to a fascia rupture (Table 2).

Perioperative blood transfusions were needed in 3/122 (2.5%) patients. No patients needed embolization. The median LOS was 2 days (IQR = 1–12).

Six months after surgery, the eGFR was reduced by a mean of 6.07 ml/min/cm³ compared to pre-operative values. According to the trifecta achievement criteria [11], the margin, ischemia and complication goal were achieved in 116/122 (95%) patients.

Discussion

The aim of the Roskilde technique is to preserve the retroperitoneal space after partial nephrectomy, while providing quick access to the renal hilum and reducing unnecessary dissection to the transperitoneal organs, which may lower the complication rate. These advantages, combined with a large working space through a transperitoneal access, may lead to the maximal benefit of this new approach. In addition, we hypothesized that perinephric formation of hematoma due to post-operative bleeding may induce pressure on the renal veins or small arteries and lead to termination of the delayed bleeding that is the most common complication after partial nephrectomy.

In accordance with this, the trifecta achievement criteria were achieved more often in our initial series with the Roskilde Technique than in previous studies describing the results of standard transperitoneal partial nephrectomies [11]. Specifically, the Roskilde technique showed shorter operating times, lower bleeding tendency, less need for blood transfusions, reduced reoperation rate and lower post-operative radiological embolization in patients with renal tumors. The differences are all clinically meaningful, but must be intercepted with caution due to the novelty of our technique and the comparison across studies [11, 13].

In many cases, our surgeries with the Roskilde technique were performed with the off clamp technique or selected

arterial clamping, which would theoretically lead to more bleeding. Therefore, the advantages of this new approach are more likely to be under-estimated than over-estimated in our study. In this regard it should be noted that the occurrence of complications with a Clavien-Dindo score ≥ 3 were lower in Roskilde technique compared to that reported in the general literature on partial nephrectomies [9, 14, 15]. Likewise, the occurrence is lower than what has been reported in retroperitoneal robot-assisted partial nephrectomy studies [9, 16].

In addition, the operative time with the Roskilde technique was shorter than that reported in the literature on retroperitoneal partial nephrectomies [9, 16]. This may be related to the large working space in the Roskilde technique compared to the retroperitoneal approach. Finally, the post-operative transfusion rate seen with the Roskilde technique was comparable to what is reported in previous studies, reporting on retroperitoneal robot assisted partial nephrectomies [17]. With the large number of patients who underwent off-clamp or selective clamping techniques in our cohort, this may indicate that the Roskilde technique can be used to reduce bleeding. In connection with the low complication rate, we found that the LOS in our cohort was shorter than what is reported in the general literature from high volume hospitals [9, 14, 17]. However, this can also be attributed to a well-established fast-track approach in our urology department [18, 19].

The potential benefits are further highlighted by the fact that oncological results were not compromised with our new technique. Thus, the occurrence of positive surgical margins with the Roskilde technique was low compared to previous studies [9, 20].

The Roskilde technique seems to be safe and feasible, with a high achievement of the trifecta criteria. It can be performed for complex large renal masses resulting in shorter operative time, less bleeding, reduced complication rates and fewer reoperations. More studies from different centers are needed to evaluate this technique and its possible benefits further.

Acknowledgments

None.

Disclosure statement

No conflict of interest and no competing financial interests exist.

ORCID

Nessn H. Azawi  <http://orcid.org/0000-0001-7519-8654>
Sara Tolouee  <http://orcid.org/0000-0001-5973-6408>

References

- [1] Capitanio U, Bensalah K, Bex A, et al. Epidemiology of renal cell carcinoma. *Eur Urol*. 2019;75:74–84.
- [2] Ljungberg B, Bensalah K, Canfield S, et al. EAU guidelines on renal cell carcinoma: 2014 update. *European Urol*. 2015;67:913–924.
- [3] MacLennan S, Imamura M, Lapitan MC, et al. Systematic review of oncological outcomes following surgical management of localised renal cancer. *Eur Urol*. 2012;61:972–993.
- [4] Gettman MT, Blute ML, Chow GK, et al. Robotic-assisted laparoscopic partial nephrectomy: technique and initial clinical experience with DaVinci robotic system. *Urology*. 2004;64:914–918.
- [5] Kaul S, Laungani R, Sarle R, et al. da Vinci-assisted robotic partial nephrectomy: technique and results at a mean of 15 months of follow-up. *Eur Urol*. 2007;51:186–191; discussion 191–192.
- [6] Scoll BJ, Uzzo RG, Chen DYT, et al. Robot-assisted partial nephrectomy: a large single-institutional experience. *Urology*. 2010;75:1328–1334.
- [7] Bergström M, Ivarsson M-L, Holmdahl L. Peritoneal response to pneumoperitoneum and laparoscopic surgery. *Br J Surg*. 2002;89:1465–1469.
- [8] Pattaras JG, Moore RG, Landman J, et al. Incidence of postoperative adhesion formation after transperitoneal genitourinary laparoscopic surgery. *Urology*. 2002;59:37–41.
- [9] Pavan N, Derweesh IH, Hampton L, et al. Retroperitoneal robotic partial nephrectomy: systematic review and cumulative analysis of comparative outcomes. *J Endourol*. 2018;32(7):591–596.
- [10] Borghesi M, Schiavina R, Chessa F, et al. Retroperitoneal robot-assisted versus open partial nephrectomy for cT1 renal tumors: a matched-pair comparison of perioperative and early oncological outcomes. *Clin Genitourin Cancer*. 2018;16:e391–e396.
- [11] Buffi N, Lista G, Larcher A, et al. Margin, ischemia, and complications (MIC) score in partial nephrectomy: a new system for evaluating achievement of optimal outcomes in nephron-sparing surgery. *Eur Urol*. 2012;62:617–618.
- [12] Ficarra V, Novara G, Secco S, et al. Preoperative aspects and dimensions used for an anatomical (PADUA) classification of renal tumours in patients who are candidates for nephron-sparing surgery. *Eur Urol*. 2009;56:786–793.
- [13] Tellini R, Antonelli A, Tardanico R, et al. Positive surgical margins predict progression-free survival after nephron-sparing surgery for renal cell carcinoma: results from a single center cohort of 459 cases with a minimum follow-up of 5 years. *Clin Genitourin Cancer*. 2019;17(1):e26–e31.
- [14] Peyronnet B, Tondut L, Bernhard J-C, et al. Impact of hospital volume and surgeon volume on robot-assisted partial nephrectomy outcomes: a multicentre study. *BJU Int*. 2018;121(6):916–922.
- [15] Mari A, Antonelli A, Bertolo R, et al. Predictive factors of overall and major postoperative complications after partial nephrectomy: results from a multicenter prospective study (The RECORd 1 project). *Eur J Surg Oncol*. 2017;43:823–830.
- [16] Stroup SP, Hamilton ZA, Marshall MT, et al. Comparison of retroperitoneal and transperitoneal robotic partial nephrectomy for Pentafecta perioperative and renal functional outcomes. *World J Urol*. 2017;35:1721–1728.
- [17] Maurice MJ, Kaouk JH, Ramirez D, et al. Robotic partial nephrectomy for posterior tumors through a retroperitoneal approach offers decreased length of stay compared with the transperitoneal approach: a propensity-matched analysis. *J Endourol*. 2017;31:158–162.
- [18] Azawi NH, Christensen T, Dahl C, et al. Pushing the envelope: laparoscopic nephrectomy as outpatient surgery. *Curr Urol Rep*. 2018;19:2.
- [19] Azawi N, Christensen T, Dahl C, et al. Hand-assisted laparoscopic versus laparoscopic nephrectomy as outpatient procedure—a prospective randomized study. *Scand J Urol*. 2018;52(1):45–51.
- [20] Petros FG, Metcalfe MJ, Yu K-J, et al. Oncologic outcomes of patients with positive surgical margin after partial nephrectomy: a 25-year single institution experience. *World J Urol*. 2018;36(7):1093–1101.